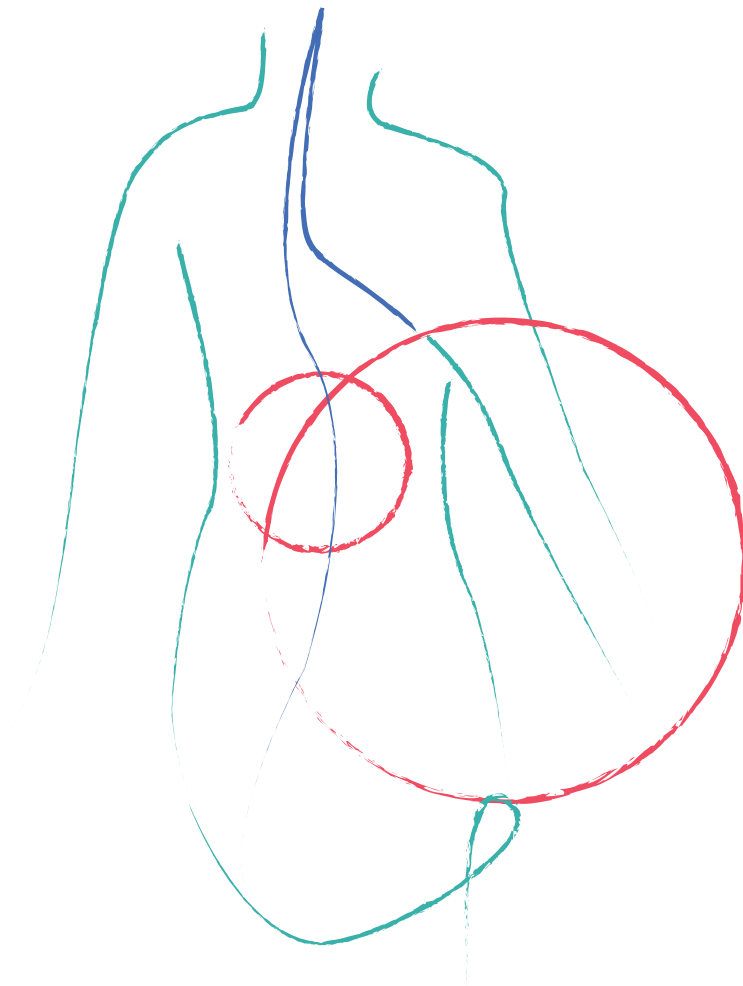


**MOG Antibody-Associated
Disease**

MOG-Ab Disease



MOG Antibody-Associated Disease (MOG-Ab disease) is a recently coined neuro-inflammatory condition that preferentially causes inflammation in the optic nerve but can also cause inflammation in the spinal cord and brain. Myelin oligodendrocyte glycoprotein (MOG) is a protein that is located on the surface of myelin sheaths in the central nervous system.^{1,2} While the function of this glycoprotein is not exactly known, MOG is a target of the immune system in this disease.³ The diagnosis is confirmed when MOG antibodies in the blood are found in patients who have repeated inflammatory attacks of the central nervous system.⁴

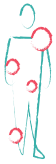Those with MOG Antibody-Associated Disease may previously have been diagnosed with Neuromyelitis Optica Spectrum Disorder (NMOSD), Transverse Myelitis (TM), Acute Disseminated Encephalomyelitis (ADEM), Optic Neuritis (ON), or Multiple Sclerosis (MS) because of the pattern of inflammation it causes including brain, spinal cord and optic nerve damage. Patients with persistently positive antibodies are at risk for recurrent events. Those with MOG Antibody-Associated Disease do not test positive for the NMO antibody called aquaporin 4 (AQP-4). MOG Antibody-Associated Disease and AQP-4 positive NMOSD are thought to have distinct immunological mechanisms.⁴ Furthermore, those with MOG Antibody-Associated Disease seem to be less likely to have other autoimmune disorders (such as rheumatoid arthritis, Hashimoto's thyroiditis etc.) than those with AQP-4 positive NMOSD.⁴



Epidemiology

Among patients with AQP-4 seronegative NMOSD, the frequency of a positive MOG antibody test ranges between 7.4% and 39%.⁵ Studies have indicated that between 40% and 58% of children diagnosed with ADEM are positive for the anti-MOG antibody.^{6,7}

Some studies have shown that those with MOG Antibody-Associated Disease are on average younger and are likely to be male compared to those with AQP-4 positive NMOSD,^{4,5,8} but other studies have shown no age differences³ and varying gender distributions.^{3,4} One study revealed a higher proportion of those of Caucasian ethnicity among MOG patients, while others have not shown this difference.³



Signs & Symptoms

MOG Antibody-Associated Disease preferentially causes inflammation in the optic nerve,⁸ but can also cause inflammation in the spinal cord, brain, and brainstem.⁵ Symptoms can include:

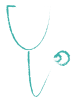- Loss or blurring of vision in one or both eyes
- Loss of color vision
- Paralysis (no motor function) of a limb or limbs
- Paraparesis (weakness) of a limb or limbs
- Loss of sensation
- Loss of bladder or bowel control
- Profound bladder retention
- Seizures^{4,9}

Those with MOG Antibody-Associated Disease are more likely to have both optic nerves affected at the same time and if the symptoms are in only one eye, the other optic nerve may show subclinical atrophy.⁴

Children can be found to have the MOG antibody in the setting of ADEM; however, a positive MOG antibody test in the setting of ADEM does not necessarily imply a course of MOG-Ab disease. In many kids, the MOG antibody disappears within 1 year and relapses do not occur. In some, the MOG antibody persists and relapses may occur. When a relapse occurs, the diagnosis of MOG-Ab disease is confirmed.

MOG Antibody-Associated Disease can also occur in relation to another condition called anti-N-methyl-D-aspartate (NMDA) receptor encephalitis.¹ NMDA receptor encephalitis is an autoimmune encephalitis that can cause psychosis, issues with memory and language, and seizures.¹

One study described symptoms and MRI findings of MOG Antibody-Associated Disease in children under the age of 7 that were similar to leukodystrophies.¹⁰ Leukodystrophies are genetic rare diseases that affect the central nervous system by disrupting myelination.



Diagnosis

There are blood tests that can test for MOG antibodies. Only cell-based assays are considered reliable for the diagnosis of MOG-Ab disease because of the improved specificity over older ELISA tests.² CSF analysis may show increased white blood cell counts in some patients during a relapse, and oligoclonal bands are not usually found.⁴

Unlike anti-AQP4 antibodies, anti-MOG antibodies may decrease over time, and may not be detectable early in the disease process or during remission, and this is especially the case for MOG Antibody-Associated Disease associated ADEM.² Those with persistent detection of anti-MOG may be more likely to have a relapsing rather than monophasic disease course.⁴

There appears to be no overlap between individuals with anti-MOG positivity and AQP-4 positivity, although there have been some isolated cases reported using the older ELISA assay.³

MRI findings are similar to those with MS and NMOSD, but there may be some differences.⁴ MOG Antibody-Associated Disease optic neuritis seems to predominantly affect the retrobulbar region, while AQP-4-associated optic neuritis is found intracranially.⁴



Acute Treatments

Treatment guidelines for MOG Antibody-Associated Disease have not been established. The following are possible treatments in the management of an acute event.

Intravenous Steroids

Although there are no clinical trials that support a unique approach to treat patients with MOG Antibody-Associated Disease, it is well recognized as a standard of care to give high-dose intravenous methylprednisolone for suspected acute myelitis or optic neuritis, generally for 3 to 5 days, unless there are compelling reasons not to. The decision to offer continued steroids or add a new treatment is often based on the clinical course and MRI appearance at the end of 5 days of steroids. Those with MOG Antibody-Associated Disease seem to respond well to steroids.^{2,3} An oral steroid taper may be helpful to prevent steroid-withdrawal relapses.

Plasma Exchange (PLEX)

PLEX is often recommended for moderate to aggressive forms of TM and ON, as is very often the case with MOG Antibody-Associated Disease, if there is not much improvement after being treated with intravenous steroids. If presenting symptoms are severe, PLEX may be initiated concurrently with steroids. There have been no prospective clinical trials that prove PLEX's effectiveness in MOG Antibody-Associated Disease, but retrospective studies of TM treated with IV steroids followed by PLEX have shown a beneficial outcome. PLEX also has been shown to be effective in other autoimmune or inflammatory central nervous system disorders. Early treatment is beneficial – PLEX is typically started within days of administering steroids, very often before the course of steroids has finished. Particular benefit has been shown if started within the acute or sub-acute stage of the myelitis or if there is continued active inflammation on MRI.

... Acute Treatments

Other Acute Treatments In cases of no response to either steroids or PLEX therapy and continued presence of active inflammation in the spinal cord, other forms of immune-based interventions may be required. The use of immunosuppressants or immunomodulatory agents may be considered in some cases. Initial presentation with aggressive forms of myelitis, or if particularly refractory to treatment with steroids and/or PLEX, aggressive immunosuppression is considered. Individuals should be monitored carefully as potential complications may arise from immunosuppression. As with all medications, risks versus benefits of aggressive immunosuppression need to be considered and discussed with the clinical care team.

Another option for treating anti-MOG associated acute inflammation is intravenous immunoglobulin (IVIG). Immunoglobulin comes from pooled blood that is donated from thousands of healthy people.¹¹ As the name suggests, IVIG is given intravenously. IVIG is generally well-tolerated. Potential adverse reactions are uncommon, but usually occur during or immediately after an infusion and include headache, nausea, muscle pain, fever, chills, chest discomfort, skin and anaphylactic reactions. Reactions after an infusion can be more serious and include migraine headaches, aseptic meningitis, renal impairment and blood clots.¹² Like corticosteroids and PLEX, there are no data confirming the value of IVIG in the setting of acute events. While most studies support the use of corticosteroids and/or PLEX in acute demyelinating syndromes, IVIG can be considered in certain circumstances.



Prognosis & Management

Initially, the presence of anti-MOG was thought to be associated with fewer relapses and better outcomes than those with AQP-4 positive NMOSD,^{5,8} but studies with longer follow-up times indicate higher relapse rates than previously reported.^{4,8}

A cohort study from 2016 found that 80% of those in the cohort had a multiphasic disease and an annualized relapse rate (AAR) of 0.9.^{4,13} They found that one third of patients with optic neuritis and around half of patients with spinal cord inflammation made a full recovery.^{4,13} In contrast, two other studies showed that the retinal neuro-axonal damage found after an acute attack of optic neuritis was as severe among anti-MOG positive individuals as individuals with AQP-4 positive NMOSD.⁴

Those with MOG Antibody-Associated Disease should consider ongoing treatment with medications that suppress the immune system. There are no FDA-approved medications for maintenance in MOG Antibody-Associated Disease, so anything prescribed is done off-label. The three primary therapies used in the US are mycophenolate mofetil (CellCept), rituximab (Rituxan), and azathioprine (Imuran). Some studies from the United Kingdom have supported the use of IVIG to prevent relapses.

All of these medications carry a risk of infections, particularly upper respiratory infections and urinary tract infections (UTIs). Good hygiene and hand washing are important if on immunosuppressants, as is having a good urologist if at risk for UTIs.

... Prognosis & Management

There is also the risk with any of these medications of the development of a rare brain infection called progressive multifocal leukoencephalopathy, or PML. PML is an infection caused by the reactivation of a virus, called the JC virus, which lives in the kidney. In someone who is immunosuppressed, this virus can escape the kidney, cross the blood-brain barrier, and enter the brain, causing profound inflammation. Although it can be treated, it is very devastating, and sometimes fatal. It is important to know that exposure to these medications in MOG Antibody-Associated Disease has not led to a known case of PML. The known rate of incidence of PML if on Rituxan is estimated at 1 in 25,000 and the rate in CellCept is estimated at 1 in 6,000 based on data from use of these medications for immunosuppression for other purposes. The manufacturer of Imuran cautions about a risk of PML with Imuran as well, but the incidence of PML on Imuran is not documented. Clinical diligence and early intervention are important if PML is suspected.

Chronic immunosuppression requires regular skin exams with a dermatologist since our immune system is our best defense against cancer cells developing, and any of these treatments can interfere with its normal functioning.

Mycophenolate mofetil and azathioprine are both twice daily pills which broadly suppress the immune system. Both medications were originally FDA approved for organ transplant rejection prophylaxis, although azathioprine now is indicated in rheumatoid arthritis and both have been widely used in several autoimmune disorders. These medications require frequent blood draws upfront, then generally twice yearly to monitor for liver toxicity and to ensure optimal immunosuppression (absolute lymphocyte count around 1 and total white blood cell count between 3 and 4).

Azathioprine Azathioprine is the medication that has been around the longest. However, while the AAR seems to be low on azathioprine, one complication with this medication is that some are not able to stay in remission on azathioprine alone and have to also be on steroids (complications of steroids will be discussed below). Additionally, a long-term study of azathioprine found that the risk of lymphatic-proliferative cancers was reported to be 3%. Common side effects include gastrointestinal upset, and this may manifest as bloating, constipation, nausea, diarrhea, and may vary throughout the course of one's time on the medication. Azathioprine is contraindicated in pregnancy, so pregnancy planning is very important. It is FDA Category D (which means don't take this drug during pregnancy unless it's life-saving) and is associated with an increased risk of miscarriages, 7% rate of congenital problems, and high rate of bone marrow suppression that recovers after birth. It is the cheapest of the medications. One study among those with MOG Antibody-Associated disease found that the mean ARR for azathioprine was 0.99, with 41% of the attacks occurring during the first 6 months, and most of these early attacks were in those who were not also being treated with corticosteroids.^{3,13}

Mycophenolate mofetil Mycophenolate mofetil has a similar effect on the gastrointestinal system, though many report that the symptoms are milder with mycophenolate as compared with azathioprine. Additionally, some complain of headaches with mycophenolate, particularly in the beginning; these tend to wane with ongoing use. Lymphoma

... Prognosis & Management

may be a risk of this medication, however there have been no cases reported in MOG Antibody-Associated Disease patients while on this medication so the risk is likely low. Mycophenolate is also contraindicated in pregnancy, so, again, planning is imperative. It is also an FDA Category D (don't take this drug during pregnancy unless it's life-saving) and carries a 45% chance of miscarriage. Of those that do not miscarry, 22% have congenital defects mostly in the face (mouth, ears).

Rituximab Rituximab is an intravascular infusion which works differently from the other two agents listed above. Rather than being a broad immunosuppressant, rituximab completely depletes one particular type of white blood cell called B-cells, which has downstream effects on the rest of the immune system. Though protocols are slightly different, in general, it is given two times twice a year (4 infusions total) and is given in an outpatient infusion center. This is because of a 30% risk of an infusion reaction without pre-medication with some cocktail of methylprednisolone, diphenhydramine and perhaps acetaminophen. The medication is quite well-tolerated. There are generally no side effects to the medication. There is no lymphoma risk with this medication. There is a monthly blood test to monitor the B-cell CD20 expression. Rituximab is safer in pregnancy than the other two previously described, (Category C; may be toxic in animals or no human data) – there are no official FDA reports of birth defects in cases of pregnancy with rituximab but babies are born with no CD20 cells. It does not appear to increase risk of infection in babies as the cells re-populate within 6-18 months. In monkey studies performed by the manufacturer, there was no toxicity on the fetus and monkey babies were born with no CD20 cells, again with no infection risks. In the largest case series published in February 2011, out of 153 women who became pregnant on rituximab, there were 4 post-natal infections and two congenital abnormalities (1 club foot, 1 heart defect) but these women were also on other immunosuppressant medications during the pregnancy, including azathioprine and mycophenolate. They concluded that rituximab does not increase the risk of congenital malformations above the natural rate of 1-2%. Planned pregnancy is still recommended. A study looking at rituximab among those with MOG Antibody-Associated disease found that three out of nine patients experienced a decline in the ARR, and most relapses occurred either soon after an infusion or at the end-of-dose period.¹³

Prednisone Low-dose prednisone is used as well, more often outside of the United States. As noted above, some clinicians also use it in combination with azathioprine for those who continue to relapse on azathioprine alone. Its use is oftentimes not favored in the US for maintenance therapy due to the potential complications associated with long-term steroid use, including diabetes, osteoporosis, weight gain, mood instability, hypertension, skin changes, etc.

IVIG IVIG has also been used as a maintenance treatment in MOG Antibody-Associated Disease. One retrospective study looked at treatment, AARs, and disability among 59 patients with MOG Antibody-Associated Disease.¹⁴ This study included 7 patients who were using IVIG as a maintenance therapy. Out of these 7 patients, 3 had relapses while on treatment with IVIG, with 3 out of 7 (43%) having treatment failure. Half of the relapses that occurred happened when weaning IVIG doses or increasing dosing

... Prognosis & Management

intervals.¹⁴ Another prospective study looking at AARs and disability in 102 children with MOG Antibody-Associated Disease found that maintenance treatment with IVIG reduced the median AAR from 2.16 to 0.51.¹⁵ They also found that 4 (33.3%) out of the 12 patients treated with maintenance IVIG relapsed.¹⁵

Studies have shown that conventional treatments for MS are not effective and may cause adverse reactions in AQP4-positive NMOSD.¹⁴ Since there is not enough information about their use in MOG Antibody-Associated Disease, and because they may not reduce relapse rates, or they may lead to adverse effects, treatments for MS are not recommended in MOG Antibody-Associated Disease.¹⁵



Long-Term Care

Rehabilitative care is essential to prevent secondary complications of immobility and to improve functional skills. It is important to begin therapy early during the course of recovery to prevent inactivity-related problems (like skin breakdown and soft tissue contractures) that lead to loss of range of motion.

Visual Deficits For patients who have had optic nerve inflammation, residual vision loss can be experienced. Patients can possibly note blurred vision, loss of color vision, difficulty with depth perception and glares or halos around lights at night. Furthermore, patients who fully recover vision after optic neuritis may experience transient returns of blurred vision during times of stress, exertion or heat exposure.

Depression During the early recovery period, family education is essential to develop a strategic plan for dealing with the challenges to independence following a return to home. Ongoing problems typically include ordering the appropriate equipment, dealing with re-entry into school, work, and community, and coping with the psychological effects of this condition on both those diagnosed with MOG Antibody-Associated Disease and their families. Being saddened or demoralized by the diagnosis of MOG Antibody-Associated Disease is appropriate. The inability to move past this grief in a reasonable period of time such that it interferes with relationships and functional living needs to be addressed and treated. Many fear that depression reflects on oneself as an inadequate ability to cope with their diagnosis and feel weak. But it is not a personal strength issue, and depression is very much a physiological manifestation and treatable. Both talking to a psychiatrist/psychologist and medication management can be beneficial, and some studies indicate a synergistic effect of combining the two. Depression can rebound and can at times become more resistant to treatment.

Spasticity Spasticity means stiffness or muscle spasms, and is often a very difficult problem to manage. Some stiffness in our muscles is necessary in order to control our movement, but when they become too tight, the result can range from slightly bothersome stiffness (particularly upon waking) to uncontrollably painful spasms. When the latter occurs, small triggers such as changes in position, temperature, humidity, or presence of infections can cause this painful spasticity. The key goal is to remain flexible with exercise, a daily stretching routine, and a bracing program

... Long Term Care

with splints, as needed. These splints are commonly used at the ankles, wrists or elbows. Medication options to relieve spasticity can be used in conjunction to these techniques, as well as therapeutic botulinum toxin injections and serial casting. The therapeutic goal is to improve function in performing specific activities of daily living (i.e., feeding, dressing, bathing, hygiene, mobility) through improving the available joint range of motion, teaching effective compensatory strategies, and relieving pain. Left untreated, severe spasticity can lead to shortening of the affected muscle or joint called contractures, further impacting mobility, rehabilitation, and independence.

An appropriate strengthening program and an aerobic conditioning regimen are recommended. Assessment and fitting for splints designed to maintain an optimal position for limbs that cannot be actively moved is an important part of spasticity management at this stage. The effects on mobility as a result of MOG Antibody-Associated Disease can vary widely, however, from paralysis to mild weakness. Either way, physical therapy is instrumental in returning function. Because physical therapists deal with many different types of injuries and diseases, it is ideal to work with one who has a particular interest in spinal cord rehabilitation when possible. Assistive devices may be necessary for weakness – it can be difficult and oftentimes humbling to take the necessary step of using an assistive device, but when faced with the alternative of broken hips, heads, and the downstream effects of lost wages or jobs, it is an important and sometimes indispensable step in maintaining independence. It is also always very important to remember to exercise, as tolerated, in order to maintain physical health and stamina.

Bladder and Bowel Complications

Another major area of concern is effective management of bowel and bladder function. Constipation is the most common bowel elimination issue. A high fiber diet, adequate and timely fluid intake, medications to regulate bowel evacuations, and regular exercise are all important contributors in helping with gastrointestinal motility. Common bladder problems include incontinence, frequency, nocturia (frequent urination at night), hesitancy, and retention. Treating incontinence, frequency, and nocturia is often easier than treating hesitancy and retention, where clean intermittent urinary catheterizations are the basic component to success. Working with a good urologist is imperative to prevent potential serious complications, particularly one who understands spinal cord disease. Urodynamic testing is necessary to determine urine retention to check risk for urinary tract infections, particularly if there is a history of UTIs to guide the urologist in terms of the best management.

Fatigue

Fatigue is the lack of mental and/or physical energy. Fatigue can be a direct result of a disease process (primary fatigue) or an indirect result (secondary fatigue). In MOG Antibody-Associated Disease, fatigue is more often thought to be a result of secondary fatigue. Examples of secondary fatigue include fatigue from medications, depression, stress, poor sleep patterns, infections, or changes in walking, which increase energy requirements. The key is to try to identify the underlying cause of the fatigue – for example, if one is not sleeping well because of pain, bladder dysfunction, or depression, this needs to be identified and addressed; not getting consistent sleep will worsen every other aspect of MOG Antibody-Associated Disease! If too much energy is exerted due to changes in walking, physical therapy can help

... Long Term Care

identify better body mechanics that will help conserve energy. When nothing else can be identified as contributing to fatigue, REST is recommended! Conserving energy such that activities are planned and paced can allow for these activities to be more enjoyable rather than stressful. Also, reorganizing home and office can help to reduce the amount of wasted energy exerted so that energy can be saved up for activities that are enjoyable. Also, exercise routines incorporated in the day can actually help build stamina and reduce fatigue in the long-run – it's also a great stress reducer! Pilates, yoga, and swimming are great, but the key is to find something enjoyable and not overdo it.

Neuropathic Pain

Changes in sensation often occur and can manifest as lack of sensation, or numbness, as well as painful sensations called neuropathic pain. This pain is described in many different ways, including burning, squeezing, stabbing, or tingling. Having the sensation of pain means the nerve signal is getting through, but in an inappropriate way. While this can get better over time, there is a long list of medications to treat these symptoms. The same medication doesn't work for everyone, so the trial and error of finding the right medication can be frustrating. Alternative therapies such as acupuncture and meditation have also been utilized, with varying success.

While the body is constantly working toward repair, once damage is done to the central nervous system, there will always be evidence of this damage, usually evidenced on an MRI. Clinical fluctuations of old symptoms, particularly in the setting of infection, stress, heat (Uhthoff's phenomenon), menstrual cycle, or anything that increases core body temperature or throws the body off of its normal course are also possible. It is important to note that this is not inflammatory driven and therefore in no way represents worsening of the condition.

Myelitis Helpline

tma.org/helpline

For questions about our organization and rare neuro-immune disorders, visit the Myelitis Helpline, an online tool developed by the Transverse Myelitis Association.

Resource Library

tma.org/tma-resource-library

To access up-to-date resources on rare neuro-immune disorders, which include symposium videos, newsletters, podcast recordings, published research summaries, information sheets and relevant external resources, visit our Resource Library.

References

- ¹ Fan S, Xu Y, Ren H, et al. Comparison of myelin oligodendrocyte glycoprotein (MOG)-antibody disease and AQP4-IgG-positive neuromyelitis optica spectrum disorder (NMOSD) when they co-exist with anti-NMDA (N-methyl-D-aspartate) receptor encephalitis. *Mult Scler Relat Disord*. 2018 Feb;20:144-152. doi: 10.1016/j.msard.2018.01.007. Epub 2018 Jan 31.
- ² Kezuka T, Ishikawa H. Diagnosis and treatment of anti-myelin oligodendrocyte glycoprotein antibody positive optic neuritis. *Jpn J Ophthalmol*. 2018 Mar;62(2):101-108. doi: 10.1007/s10384-018-0561-1. Epub 2018 Feb 14.
- ³ Dos Passos GR, Oliveira LM, da Costa BK, et al. MOG-IgG-Associated Optic Neuritis, Encephalitis, and Myelitis: Lessons Learned From Neuromyelitis Optica Spectrum Disorder. *Front Neurol*. 2018 Apr 4;9:217. doi: 10.3389/fneur.2018.00217. eCollection 2018.
- ⁴ Weber MS, Derfuss T, Metz I, Brück W. Defining distinct features of anti-MOG antibody associated central nervous system demyelination. *Ther Adv Neurol Disord*. 2018 Mar 29;11:1756286418762083. doi: 10.1177/1756286418762083. eCollection 2018.
- ⁵ Lechner C, Baumann M, Hennes EM, et al. Antibodies to MOG and AQP4 in children with neuromyelitis optica and limited forms of the disease. *J Neurol Neurosurg Psychiatry*. 2016 Aug;87(8):897-905. doi: 10.1136/jnnp-2015-311743. Epub 2015 Dec 8.
- ⁶ Brilot F, Dale RC, Selter RC, et al. Antibodies to native myelin oligodendrocyte glycoprotein in children with inflammatory demyelinating central nervous system disease. *Ann Neurol*. 2009 Dec;66(6):833-42. doi: 10.1002/ana.21916.
- ⁷ Baumann M, Sahin K, Lechner C, et al. Clinical and neuroradiological differences of paediatric acute disseminating encephalomyelitis with and without antibodies to the myelin oligodendrocyte glycoprotein. *J Neurol Neurosurg Psychiatry*. 2015;86(3):265-272.
- ⁸ Cobo-Calvo A, Ruiz A, Maillart E, et al. Clinical spectrum and prognostic value of CNS MOG autoimmunity in adults: The MOGADOR study. *Neurology*. 2018 May 22;90(21):e1858-e1869. doi: 10.1212/WNL.0000000000005560. Epub 2018 Apr 25.
- ⁹ Gutman JM, Kupersmith M, Galetta S, Kister I. Anti-myelin oligodendrocyte glycoprotein (MOG) antibodies in patients with optic neuritis and seizures. *J Neurol Sci*. 2018 Apr 15;387:170-173. doi: 10.1016/j.jns.2018.01.042. Epub 2018 Feb 2.
- ¹⁰ Hacohen Y, Rossor T, Mankad K, et al. 'Leukodystrophy-like' phenotype in children with myelin oligodendrocyte glycoprotein antibody-associated disease. *Dev Med Child Neurol*. 2018 Apr;60(4):417-423. doi: 10.1111/dmcn.13649. Epub 2017 Dec 30.
- ¹¹ Guo Y, Tian X, Wang X, Xiao Z. Adverse Effects of Immunoglobulin Therapy. *Front Immunol*. 2018 Jun 8;9:1299. doi: 10.3389/fimmu.2018.01299. eCollection 2018.
- ¹² Cherin P, Marie I, Michallet M, et al. Management of adverse events in the treatment of patients with immunoglobulin therapy: A review of evidence. *Autoimmun Rev*. 2016 Jan;15(1):71-81. doi: 10.1016/j.autrev.2015.09.002. Epub 2015 Sep 16.



The Transverse Myelitis Association

PO Box 826962

Philadelphia, PA 19182-6962

phone: +1 (855) 380-3330

email: info@myelitis.org

website: www.myelitis.org

facebook.com/myelitis

twitter.com/myelitis

instagram.com/myelitis