



**Acute Flaccid  
Myelitis**

**AFM**

---





**Acute Flaccid Myelitis (AFM)** is a type of inflammation in the spinal cord that has specific clinical and MRI features. AFM abnormalities noted on MRI are predominantly found in the gray matter (lower motor neuron) of the spinal cord. In 2012, an outbreak of AFM occurred in California and more cases were reported in the summer and fall of 2014, 2016, and 2018 across the United States. Non-polio enteroviruses have been implicated as potential causal factors in the development of AFM. The enterovirus D68 and enterovirus A71 have been suspect in many of these cases, although others such as coxsackie viruses have been implicated as well. Enterovirus D68 most often causes a respiratory illness and has been circulating in the United States during the summer and fall every two years since 2014, which coincides with the increase of cases of AFM seen every other year. It has not been definitively proven that these particular viruses have directly caused cases of AFM but the temporal onset of neurological symptoms with infections produced by those viruses implicate them as direct or indirect triggers of the neurological problem.

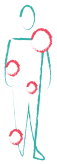

## Epidemiology

---

There are no conclusive studies that identify the actual numbers of individuals specifically affected by AFM, but from 2014 to 2018, the CDC confirmed over 500 reports of those affected by AFM. Not all cases are reported to the CDC nor confirmed by the CDC, so this number is likely an underestimation. There have been reports of AFM in both children and adults, but AFM cases primarily affect children under the age of 18.

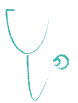Until the recent characterization of AFM in 2014, it is likely that many individuals with initial presentation of flaccid limb weakness and/or paralysis have been diagnosed as having transverse myelitis or Guillain Barre Syndrome in previous years.



## Signs & Symptoms

---

Most of those diagnosed with AFM report having a respiratory or gastrointestinal illness before the onset of weakness. The predominant presentation is a rapid onset of weakness that may affect the limbs, face, oropharyngeal muscles, or the muscles that control breathing. Those with AFM may not be able to breathe, swallow, or move their eyes normally. Weakness varies greatly ranging from mild to very severe. AFM may result in weakness, partial paralysis, or total paralysis of just one limb or all limbs. The pattern of paralysis and how individuals present are widely variable. Weakness most often occurs in proximal muscles, meaning the muscles closest to the center of the body. Pain in the neck, back, or limb may be an early symptom. Autonomic instability, such as issues with heart rate, may occur as well. Since it is mainly the gray matter of the spinal cord that is damaged in individuals with AFM, they may not have bladder or bowel dysfunction or issues with sensation. However, some individuals may have inflammation in both the white and gray matter of the spinal cord (upper and lower motor neuron), so some of those with AFM may experience impaired sensation, bladder, and/or bowel dysfunction.



## Diagnosis

---

Acute flaccid myelitis is diagnosed based upon clinical exam, magnetic resonance imaging (MRI) of the spinal cord, and analysis of cerebrospinal fluid (CSF) (usually with increased white blood cells or pleocytosis). On MRI of the spinal cord, AFM lesions are longitudinal throughout the grey matter (the anterior horn cells). Sometimes imaging may appear normal early in the disease, but repeat imaging shows the lesions. In some situations, electrophysiological studies of the nerves and muscle (called nerve conduction and electromyogram [NCS/EMG]) may help to determine if there is injury to the lower motor neuron. Testing may also include blood draws, respiratory tract samples or collection of other bodily fluids to determine if a viral or infectious cause is present.



## Acute Treatments

Specific treatments and intervention for AFM have not yet been identified, but some of the treatments available for transverse myelitis have been used (high dose intravenous (IV) steroids, intravenous immunoglobulin (IVIG), and plasma exchange (PLEX)). The purpose of the treatments is to attempt to reduce inflammation in the spinal cord and further prevent the individual's immune system from causing damage. IVIG has antibodies that may have effect on limiting inflammation or neutralization or replication of enteroviruses and is widely used in treating AFM. The data on use of steroids or PLEX are mixed. Fluoxetine was used in several centers in the US in 2016 and was well tolerated but was not associated with improved outcomes among treated children. As is usual with treatment of rare neuro-immune disorders, in which placebo-controlled trials are difficult to perform, treatment must be individualized. Physical and occupational therapy are also believed to be significant for recovery in AFM.



## Prognosis

Recovery varies among individuals with AFM. Most do not recover fully, but patients do regain strength and motor function over time to varying degrees. The most affected muscle may be the least likely to recover. Again, physical and occupational therapy are also believed to be critical for recovery in AFM.



## Rehabilitation & Symptom Management

After the acute phase, rehabilitative care to improve functional skills and prevent secondary complications of immobility involves both psychological and physical accommodations. Rehabilitation may begin in the intensive care unit with the goal to transition individuals to an inpatient or outpatient rehabilitation program. There is very limited information in the medical literature specifically dealing with rehabilitation after AFM. However, much has been written regarding recovery from spinal cord injury (SCI), in general, and this literature applies. The physical issues include speech and oral motor skills training, bowel and bladder management, maintenance of skin integrity, spasticity, activities of daily living (i.e., dressing), mobility, sexual dysfunction (for adults), and pain.

The long-term management of AFM requires attention to a number of issues. These are the residual effects of any spinal cord injury, including AFM. In addition to chronic medical problems, there are the ongoing issues of ordering the appropriate equipment, reentry into school, re-socialization into the community, and coping with the psychological effects of this condition by the patients and their families. During the early recovery period, family education is essential to develop a strategic plan for dealing with the challenges to independence following return to the community.

**Rehabilitation** It is important to begin occupational and physical therapies early during the course of recovery to prevent the inactivity related problems of skin breakdown and soft tissue contractures that lead to a decreased range of motion. Assessment and fitting

## ... Rehabilitation & Symptom Management

---

for splints designed to passively maintain an optimal position for limbs that cannot be actively moved is an important part of the management at this stage.

Activity-based rehabilitation includes weight-bearing exercise, functional electrical stimulation (FES), locomotor training, task-specific practice, and massed practice. Individuals with AFM may not respond to FES, but therapists can adjust FES parameters to try to get a better muscle contraction. FES even without obvious muscle contraction may have benefits. Weight-bearing exercise has been shown to improve bone mineral density, range of motion, muscle tone, and bowel function. Vibration during weight bearing may also activate denervated muscles. Weight-bearing exercises can progress to locomotor training on the treadmill with appropriate orthotics. Aqua therapy can be helpful for stretching tight muscles. Task specific practice involves relearning functions that were lost due to AFM such as bed mobility and coming to a seated position, feeding, dressing, and personal hygiene. Some children who were younger when AFM onset occurred will have to learn these for the first time. Massed practice involves repetition and increased level of activity. It has been shown that children can tolerate up to 5 hours of therapy a day. It is important to keep in mind that spinal cord injuries in children result in risks of skeletal subluxations and decreased bone mineral density which can result in fractures.

Other rehabilitation factors to consider are pulmonary management for those with ventilator dependence, and speech and language pathologists for those children with difficulty swallowing (dysphagia) and talking (dysphonia).

Individuals with AFM may find ordinary tasks such as dressing, bathing, grooming, and eating very difficult. Many of these obstacles can be mastered with training and specialized equipment. For example, long handled sponges can make bathing easier as can grab bars, portable bath seats and hand-held shower heads. For dressing, elastic shoe-laces can eliminate the need to tie shoes while other devices can aid in donning socks. Occupational therapists are specialists in assessing equipment needs and helping people with limited function perform activities of daily living. A home assessment by an experienced professional is often helpful. Physical therapists assist with mobility. Besides teaching people to walk and transfer more easily, they can recommend mobility aids. This includes everything from canes (single point vs. small quad cane vs. large quad cane) to walkers (static vs. rolling vs. rollator) and braces. For a custom-fabricated orthotic (brace), an orthotist is necessary. Careful thought should go into deciding whether the brace should be an ankle-foot orthosis, whether it should be flexible or stiff, and what angle the foot portion should be in relationship to the calf portion. Some will benefit by a knee-ankle foot orthosis. Each person should be evaluated individually. The best results occur when a physician coordinates the team so that the therapists and orthotists are united on what is to be achieved. The physician best trained to take this role is the physiatrist.

### **Nerve Transfers**

Some individuals may benefit from nerve transfer procedures, which is when nerves are taken from one area of the body and are transferred to a denervated nerve. The previous experience derived from obstetric brachial plexus injury has guided some of the approaches in patients with AFM. The value in recovery of selected upper

## ... Rehabilitation & Symptom Management

---

extremity muscle groups in AFM patients appears promising although there is still need for a well-documented and validated approach to prove their beneficial outcomes. There are some cases reported in the literature of successful nerve transfers, but additional studies are needed to learn the correct timing for when nerve transfers should occur after onset.

**Bladder Function** Bladder dysfunction may not occur in all individuals with AFM. Immediately after the onset of AFM, there is frequently a period of transient loss or depression of neural activity below the involved spinal cord lesion, referred to as “spinal shock,” which lasts about 3 weeks. Following this period, two general problems can affect the bladder. The bladder can become overly sensitive, and empty after only a small amount of urine has collected, or relatively insensitive, causing the bladder to become over extended and overflow. An overly distended bladder increases the likelihood of urinary tract infections and, in time, may threaten the health of the kidneys. Depending on the dysfunction, treatment options include timed voiding, medicines, external catheters for males (a catheter connected to a condom), padding for females, intermittent internal self-catheterization, an indwelling catheter, or electrical stimulation. Surgical options may be appropriate for some people.

**Bowel Function** Another major area of concern is effective management of bowel function. A common problem in spinal cord injury is difficulty with evacuation of stool, although fecal incontinence can also occur. The neurologic pathways for defecation are similar to those of the bladder. Many lacking voluntary control of the bowel may still be able to achieve continence by diet, strategic use of stool softeners and fiber, and the technique of rectal stimulation. Other aids include suppositories, mini-enemas, anal irrigation, and oral medications. A high-fiber diet, adequate and timely fluid intake, and medications to regulate bowel evacuations are the basic components of success. Regular evaluations by medical specialists for adjustment of the bowel program are recommended to prevent potentially serious complications. There are some surgical options, although this is rarely necessary.

**Sexual Dysfunction** Sexual dysfunction involves similar innervation and analogous syndromes as those found in bladder dysfunction. Treatment of sexual dysfunction in adults diagnosed with AFM should take into account baseline function before the onset of AFM. Until we learn more about this issue in AFM, individuals experiencing sexual dysfunction may want to refer to the strategies used in individuals with other rare neuro-immune disorders or spinal cord injuries.

**Skin Breakdown** Skin breakdown occurs if the skin is exposed to pressure for a significant amount of time, without sensation or the strength to shift position as necessary. Sitting position should be changed at least every 15 minutes. This can be accomplished by standing, by lifting the body up while pushing down on armrests, or by just leaning and weight shifting. Wheelchairs can be supplied with either power mechanisms of recline or tilt-in-space to redistribute weight bearing.

A variety of wheelchair cushions are available to minimize sitting pressure. Redness that does not blanch when finger pressure is applied may signal the beginning of a

## ... Rehabilitation & Symptom Management

---

pressure ulcer. Good nutrition, vitamin C, and avoidance of moisture all contribute to healthy skin. Pressure ulcers are much easier to prevent than to heal.

**Spasticity** Spasticity may be an issue in AFM, particularly when a cervical spine lesion involved both the gray matter and the white matter. Damage to the white matter in the neck leads to a spastic weakness in the legs and can be seen in some AFM patients. The goal is to maintain flexibility with a stretching routine using exercises for active stretching and a bracing program with splints for a prolonged stretch. These splints are commonly used at the ankles, wrists, or elbows. Also recommended are appropriate strengthening programs for the weaker of the spastic muscles acting on a joint and an aerobic conditioning regimen. These interventions are supported by adjunctive measures that include antispasticity drugs (e.g., diazepam, baclofen, dantrolene, tizanidine), therapeutic botulinum toxin injections, and serial casting. The therapeutic goal is to improve the function of the individual in performing specific activities of daily living (i.e., feeding, dressing, bathing, hygiene, mobility) by improving the available joint range of motion, teaching effective compensatory strategies, and relieving pain.

**Pain** Pain is common following AFM. The first step in treating pain effectively is obtaining an accurate diagnosis. Unfortunately, this can be very difficult. Causes of pain include muscle strain from using the body in an unaccustomed manner, nerve compression (i.e., compression of the ulnar nerve at the elbow due to excessive pressure from resting the elbow on an armrest continuously) or dysfunction of the spinal cord from the damage caused by the inflammatory attack. Muscle pain might be treated with analgesics, such as acetaminophen (Tylenol), non-steroidal, anti-inflammatory drugs such as naproxen or ibuprofen (Naprosyn, Aleve, Motrin), or modalities such as heat or cold. Nerve compression might be treated with repositioning and padding (i.e., an elbow pad for an ulnar nerve compression).

Nerve pain can be a significant challenge to find effective treatment. Nerve messages traveling through the damaged portion of the spinal cord may become scrambled and misinterpreted by the brain as pain. Besides the treatments listed above, certain antidepressants such as amitriptyline (Elavil), or anticonvulsants, such as carbamazepine, phenytoin, or gabapentin (Tegretol, Dilantin, Neurontin) may be helpful. Stress and depression should also be addressed since these conditions make pain harder to tolerate.

**Depression** Individuals with AFM should be educated about the effect of AFM on mood regulation and routinely screened for the development of symptoms consistent with clinical depression. Warning signs that should prompt a complete evaluation for depression include failure to progress with rehabilitation and self-care, worsening fixed low mood, pervasive decreased interest, and/or social and professional withdrawal. A preoccupation with death or suicidal thoughts constitutes a true psychiatric emergency and should lead to prompt evaluation and treatment. Depression in AFM is similar to the other neurologic symptoms patients endure, which are mediated by the effects of the immune system on the brain. While the prevalence of depression among individuals with AFM is not known, depression is remarkably prevalent in

## ... Rehabilitation & Symptom Management

---

TM, occurring in up to 25% of those diagnosed at any given time, and is largely independent of the patient's degree of physical disability. Depression is not due to personal weakness or the inability to "cope." It can have devastating consequences; not only can depression worsen physical disability (such as fatigue, pain, and decreased concentration) but it can have lethal consequences. Despite the severity of the clinical presentation of depression in AFM, there is a very robust response to combined aggressive psychopharmacologic and psychotherapeutic interventions.

### **Autonomic Dysreflexia**

Autonomic dysreflexia can occur when a spinal cord is damaged above the T6 level. Symptoms can include nausea, sweating, fast heart rate and/or profound blood pressure changes (up or down). Episodes can be triggered by urinary tract infections, catheterizations, constipation or painful events in the lower extremities. Care should be given to minimize triggers and manage any blood pressure variations during an event.

### **Respiratory Dysfunction**

A subset of patients with aggressive forms of AFM may experience marked respiratory and diaphragmatic dysfunction. It may occur when the neurons that control diaphragm movement innervated by the phrenic nerve, or intercostal muscles that partially control the mechanics of breathing, fail due to damage of motor neurons in the spinal cord. Thus, patients can have difficulty breathing and require long term ventilatory support. Over months or years patients can be weaned from the ventilator as motor control of the diaphragm comes back, but in some patients it has not yet returned. Strategies such as a diaphragm pacer are being used now although there is still need for a validated demonstration of its efficacy. Those with respiratory issues may also experience issues with heart rate, like tachycardia (high heart rate) and bradycardia (low heart rate).

---

### **Myelitis Helpline**

[tma.org/helpline](https://tma.org/helpline)

For questions about our organization and rare neuro-immune disorders, visit the Myelitis Helpline, an online tool developed by the Transverse Myelitis Association.

### **Resource Library**

[tma.org/tma-resource-library](https://tma.org/tma-resource-library)

To access up-to-date resources on rare neuro-immune disorders, which include symposium videos, newsletters, podcast recordings, published research summaries, information sheets and relevant external resources, visit our Resource Library.





**The Transverse Myelitis Association**

PO Box 826962

Philadelphia, PA 19182-6962

phone: +1 (855) 380-3330

email: [info@myelitis.org](mailto:info@myelitis.org)

website: [www.myelitis.org](http://www.myelitis.org)

[facebook.com/myelitis](https://facebook.com/myelitis)

[twitter.com/myelitis](https://twitter.com/myelitis)

[instagram.com/myelitis](https://instagram.com/myelitis)